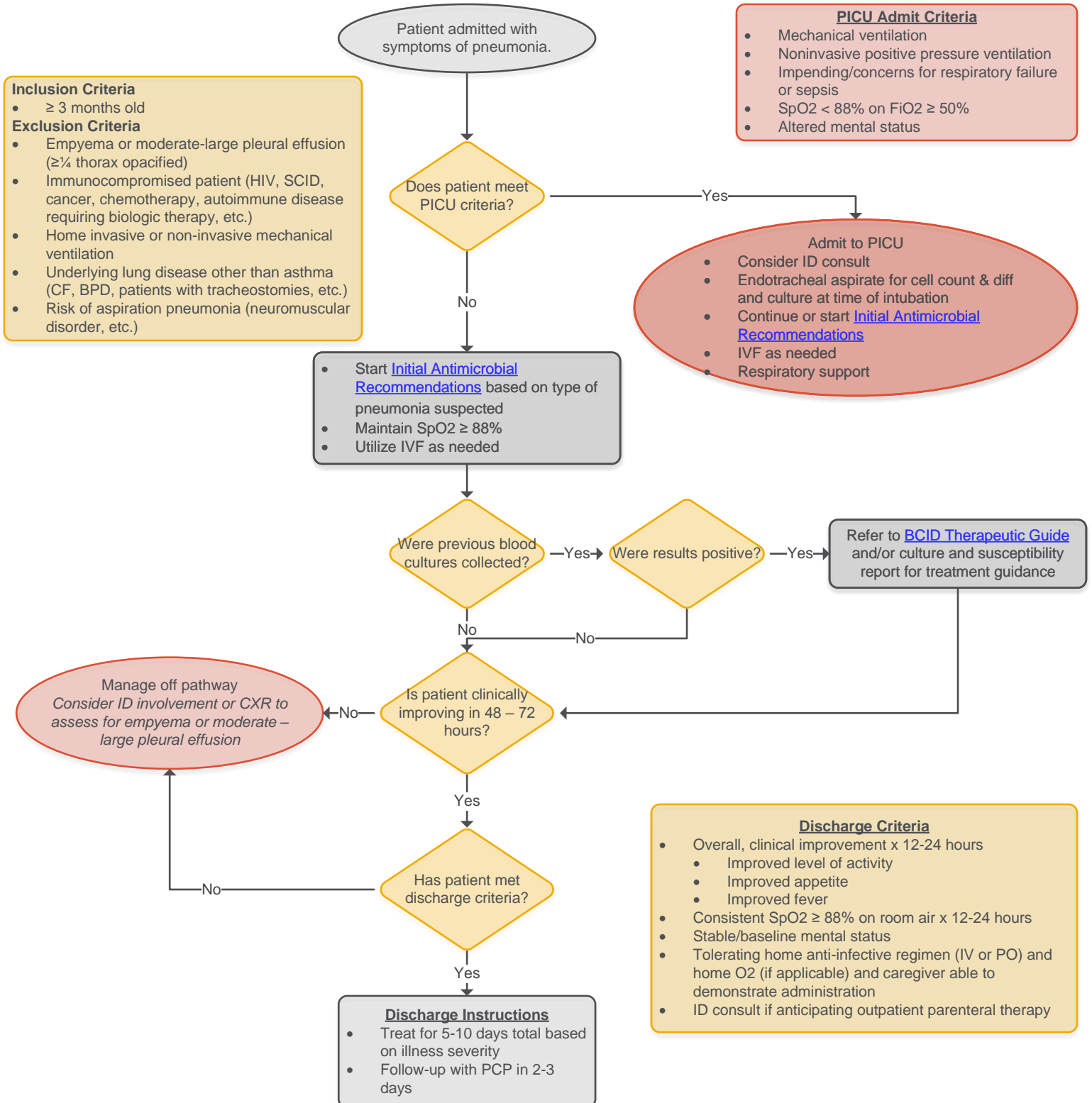


COMMUNITY ACQUIRED PNEUMONIA (SIMPLE) CLINICAL PATHWAY INPATIENT



Disclaimer: Pathways are intended as a guide for practitioners and do not indicate an exclusive course of treatment nor serve as a standard of medical care. These pathways should be adapted by medical providers, when indicated, based on their professional judgement, and taking into account individual patient and family circumstances.

COMMUNITY ACQUIRED PNEUMONIA (SIMPLE) CLINICAL PATHWAY INPATIENT



Community Acquired Pneumonia Etiology Characteristics

	Viral Pneumonia	Bacterial Pneumonia	Atypical Bacterial Pneumonia
Etiologies	RSV, hMPV, rhinovirus, parainfluenza, influenza, coronaviruses, adenoviruses	<i>Streptococcus pneumoniae</i> , <i>Haemophilus influenzae</i>	<i>Mycoplasma pneumoniae</i> , <i>Chlamydia pneumoniae</i>
Age	All ages; most common etiology in children < 5 years	All ages	Most common in ages > 5 years
Onset	Gradual	Abrupt, rapid progression	Gradual, slow progression
Symptoms	Non-productive cough typically preceded by URI symptoms (coryza, pharyngitis, mild fever, etc.)	Fever, chills, cough (± productive), ± localized chest pain	Non-productive, irritative cough, typically preceded by headache, malaise, pharyngitis
Physical Exam Findings	Non-toxic appearing; diffuse, bilateral auscultatory findings of w heezing or crackles	Ill appearance, tachypnea, respiratory distress, focal auscultatory findings of rales or "tubular" breath sounds; dullness to precussion over the involved lung area	Well-appearing; diffuse rales, crackles, rhonchi, or w heezes
Radiographic Findings	Diffuse, bilateral interstitial infiltrates	Alveolar infiltrates, lobar, or segmental consolidation, "round pneumonia", complications may include pleural effusion, empyema, lung abscess, necrotizing pneumonia or pneumatocele	Diffuse, bilateral interstitial infiltrates